



PATIENT PRESENTING CLINICAL SIGNS

PATIENT Stitch Kadinger
History: Repeat ultrasound as patient is clinical worsening with marked increase in WBC count. Did inadvertently receive high calorie food. Previous ultrasound (8/1) showed pancreatitis, gastroenteropathy, and lymphadenomegaly.

SPECIES Canine
Physical Examination: N/A.
Urinalysis: N/A.

BREED Chihuahua
CBC: Leukocytosis.

SEX Radiographic Findings: N/A.

MN ULTRASONOGRAPHIC EXAMINATION OF THE ABDOMEN

AGE *Urinary System*

9 years N/A.

Reproductive System

WEIGHT 9 #
N/A.

Adrenal Glands

INTERPRETED BY N/A

Remo Lobetti, BVSc,
MMedVet (Med), PhD, Dipl.
ECVIM
Spleen

N/A

IMAGING PERFORMED BY *Liver*

Sonya Myers, DVM
N/A

HOSPITAL NAME *Gastrointestinal*

Oviedo Veterinary Care and
Emergency
REFERRING VET Dr Rivera
Normal appearance of the duodenum, ileo-cecal junction, and colon with no loss of layering, normal wall thickness (duodenum 0.39 cm) and peristaltic activity, and no distension of the lumen. Thickening of the stomach (0.46 cm) and mild segmental thickening of the small intestine (up to 0.51 cm) with no loss of layering or distension of the lumen and normal peristalsis. Large amount of fluid within the stomach.

Pancreas

INVOICE 303174
Enlarged (right 1.2 cm, left 1.3 cm) with a diffuse hyperechogenic appearance of the right lobe and a hypoechogenic appearance of the left lobe. Irregular capsule. Hyperechogenic appearance of the mesentery and fat surrounding the pancreas.

DATE *Free Abdomen*

8/5/22 Mesenteric lymphadenomegaly with normal shape and echogenic appearance.
No ascites.



PATIENT

Stitch Kadinger

SPECIES

Canine

BREED

Chihuahua

SEX

MN

AGE

9 years

WEIGHT

9 #

INTERPRETED BY

Remo Lobetti, BVSc,
MMedVet (Med), PhD, Dipl.
ECVIM

IMAGING PERFORMED BY

Sonya Myers, DVM

HOSPITAL NAME

Oviedo Veterinary Care and
Emergency

REFERRING VET

Dr Rivera

INVOICE

303174

DATE

8/5/22

ULTRASONOGRAPHIC FINDINGS

Primary Findings:

- Pancreatitis.
- Gastro-enteropathy.
- Lymphadenomegaly.

Secondary Findings:

- None.

INTERPRETATION OF THE FINDINGS & FURTHER RECOMMENDATIONS

This appearance of the pancreas and GI tract is similar to the changes evident on the previous ultrasound and this consistent with chronic active pancreatitis and most likely a secondary gastroenteropathy and associated lymphadenomegaly.

No evidence of bile duct obstruction, pancreatic abscessation or worsening peritonitis.

Further assessment would be fecal analysis, cPL/PSL assay, cobalamin assay, and endoscopy of the upper GI tract with biopsies.

Therapy would be low-fat intestinal diet, fluid therapy, opioid analgesics, correction of electrolyte anomalies (if present) gastric protectants, anti-emetics, metoclopramide, and a short course of prednisolone (1 mg/kg sid for 3 days), as the latter has been shown to improve the outcome and shorten the duration of pancreatitis.



PATIENT **IMAGES**
 Stitch Kadinger **Stomach**

SPECIES

Canine

BREED

Chihuahua

SEX

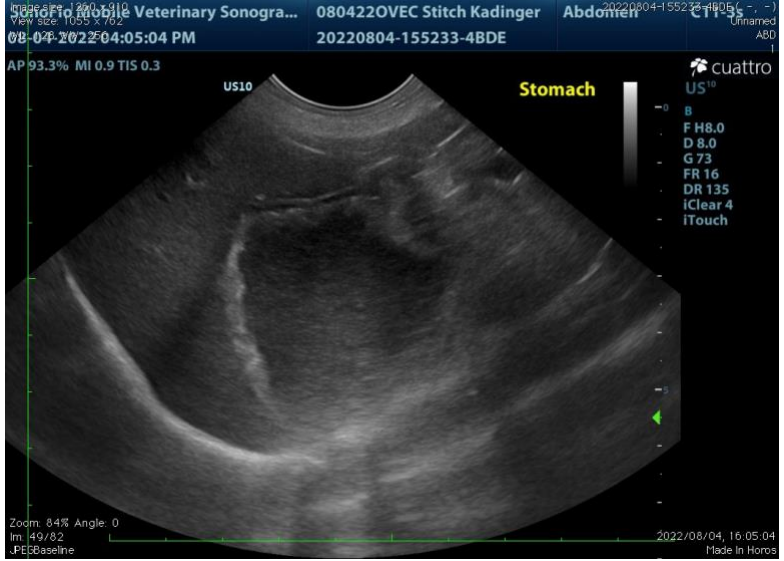
MN

AGE

9 years

WEIGHT

9 #



Pancreas

INTERPRETED BY

Remo Lobetti, BVSc,
 MMedVet (Med), PhD, Dipl.
 ECVIM

IMAGING PERFORMED BY

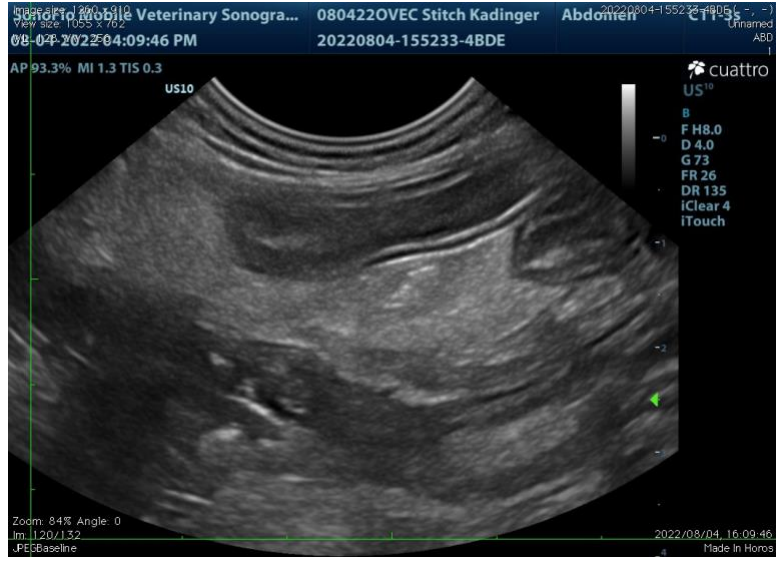Sonya Myers, DVM

HOSPITAL NAME

Oviedo Veterinary Care and
 Emergency

REFERRING VET

Dr Rivera



INVOICE

303174

DATE

8/5/22

The information and recommendations provided are based on the images presented by the referring veterinarian. No evaluation can be communicated regarding pathology that was not visible in the image/video clips provided.

Thank you for this referral. If the clinical or image interpretation does not parallel your findings or if I can be of any further assistance, please contact me.

Remo Lobetti, BVSc, MMedVet (Med), PhD, Dipl. ECVIM (Internal Medicine)
rlobetti@mweb.co.za